

Michael Cosimini


PEARLS AND PITFALLS FROM DEVELOPING A SERIOUS TABLETOP GAME

 @MichaelCosimini

 @EmpiricGame

 @EmpiricGame

DISCLOSURES



.... and I have not yet played all the games

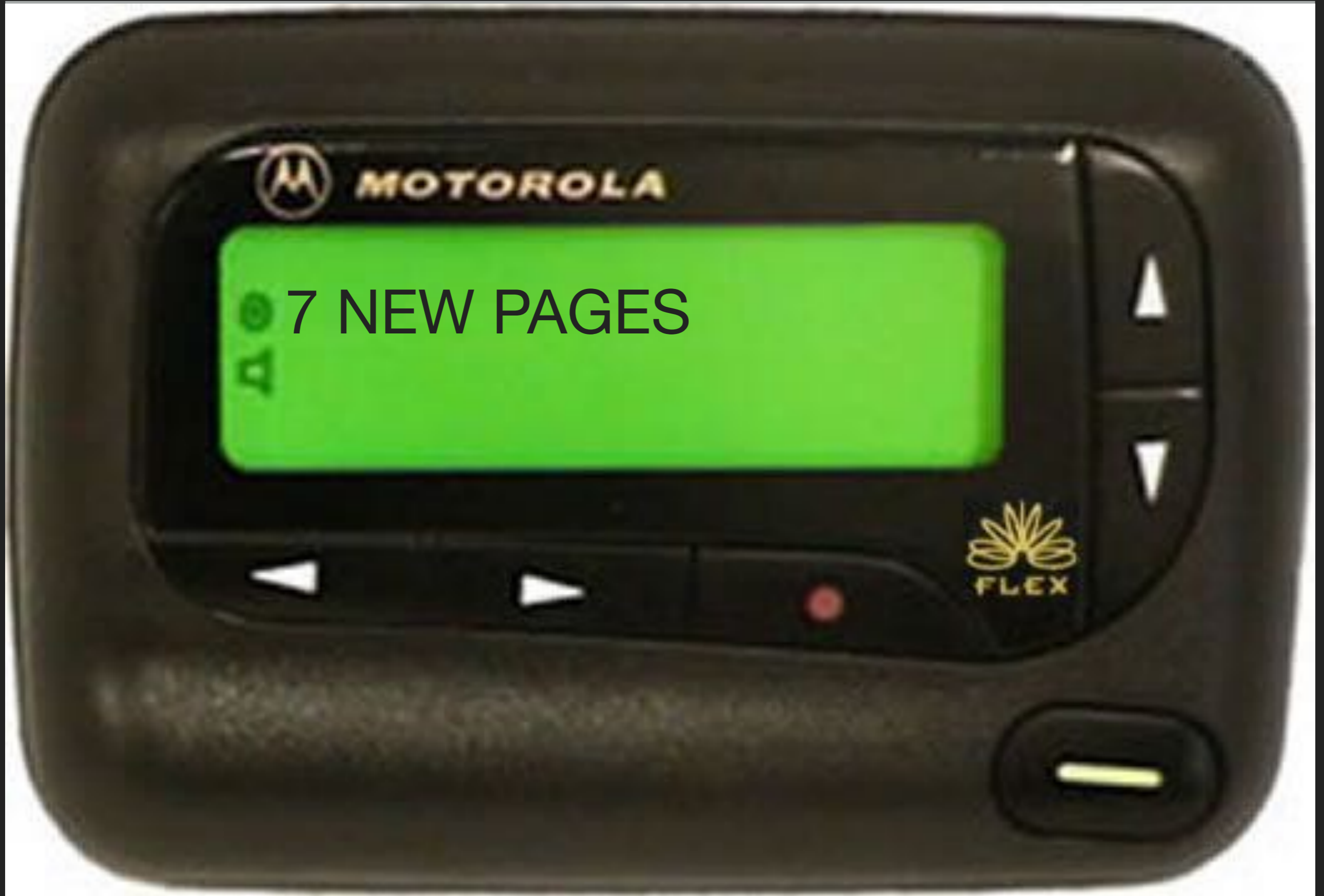THE SETTINGS

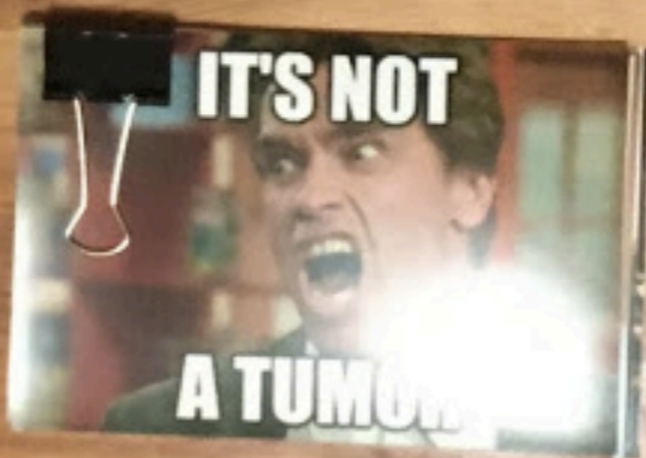
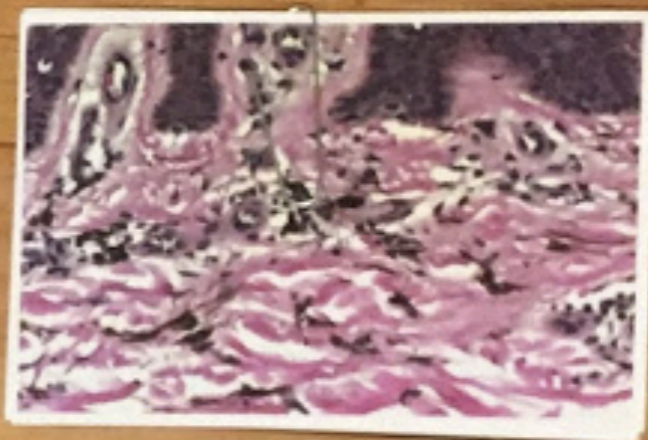
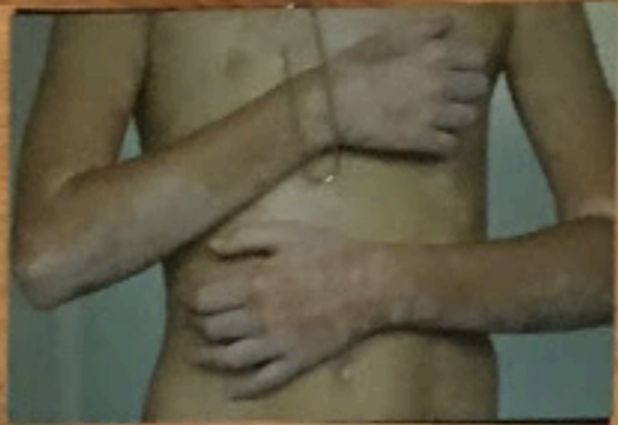
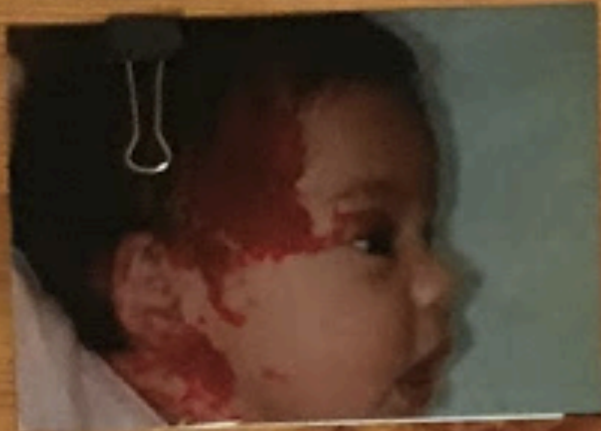- ▶ Small group (2-8) teaching on wards
- ▶ 1:1 clinic

MEDICAL STUDENTS : SAVVY CONSUMERS OF EDUCATION

- ▶ Average \$739 spent on educational resources
- ▶ Average 4.4 online study tools for USMLE STEP 1

RESIDENTS



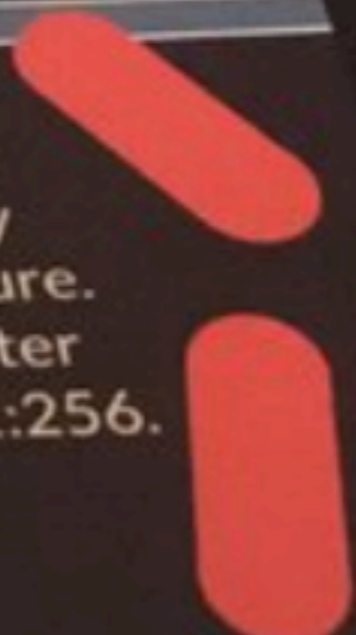




BARTONELLA ADENITIS

② ○

Six-year-old with unilateral cervical lymphadenopathy and kitten exposure. Bartonella IgG titer is greater than 1:256.



Redbook 201



25min



MS1+



2-4 Players



VARICELLA EXPOSURE

Three-day-old full term infant born to an unvaccinated mother who developed primary varicella four days prior to delivery.



AAFP 2016

OTITIS MEDIA

One-year-old with fever of 39.5° otalgia, and otoscopy consistent with unilateral acute otitis media. No recent antibiotics.



AAFP 2013

CLOSTRIDIODES DIFFICILE

Eleven-year-old recently treated with antibiotics presenting with *Clostridioides difficile* colitis and mild symptoms.



IDSA 2018

ROCKY MOUNTAIN SPOTTED FEVER

Seven-year-old with fever, headache, and acral rash with palm and sole involvement after travel to Missouri. CBC shows thrombocytopenia. Treatment is started while awaiting serology.



CDC 2017

DOG BITE

Fifteen-year-old with dog bite. Up to date on tetanus.



IDSA 2014

DOXYCYCLINE TETRACYCLINE

Binds to 30s of bacterial ribosome



DOXYCYCLINE

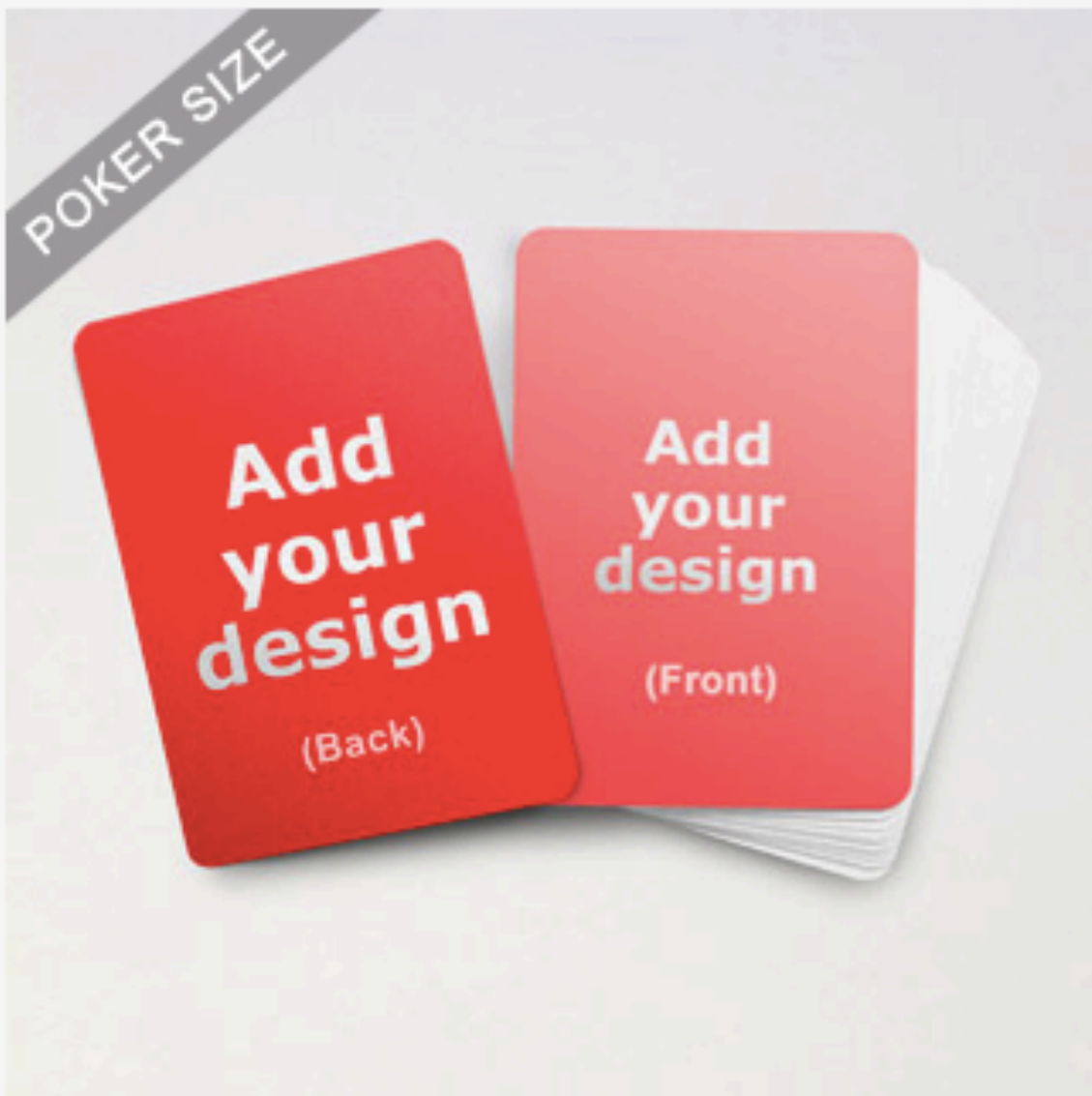STAPHYLOCOCCUS, NON-ENTERIC GRAM NEGATIVE, ATYPICAL BACTERIA, TICK BORNE AND ZOONOTIC INFECTIONS






-
- ▶ Minimum viable and test it!
 - ▶ Online vector editing and photoshop
 - ▶ Print on demand
 - ▶ Feedback on PnP/PDF
 - ▶ People do what they do
 - ▶ Design for human animal
 - ▶ Make it smaller and simpler
 - ▶ Game does not stand alone
 - ▶ Social Media
 - ▶ Video!
- ▶ Mailing people copies
 - ▶ Google forms
 - ▶ Iteration on printed copies
 - ▶ QR codes

VISUAL DESIGN




View



Sample



Sample



close-up

Custom Game Cards (63 x 88mm)

See how we're going more environmentally friendly »

Quantity	Price/deck
No set-up charge	
1-5	\$13.90
6-29	\$11.60
30-49	\$9.55
50-99	\$7.95
100-249	\$6.35
250-499	\$4.90
500-999	\$3.60
1000-2499	\$2.70
2500-4999	\$2.00
5000-7499	\$1.60
7500-9999	\$1.40
10000-12499	\$1.25
12500-14999	\$1.10
15000+	\$0.99
Need 2500+ decks with different designs or a specific customization?	Contact us for quote
Applies to duplicate decks See delivery options »	

Card stock: [\[see details\]](#)

(S30) Standard Smooth

Size of deck:

Up to 55 cards

Print type: [\[see details\]](#)

Full color print

Finish: [\[see details\]](#)

MPC game card finish

Packaging: [\[view\]](#)

Shrink-wrapped

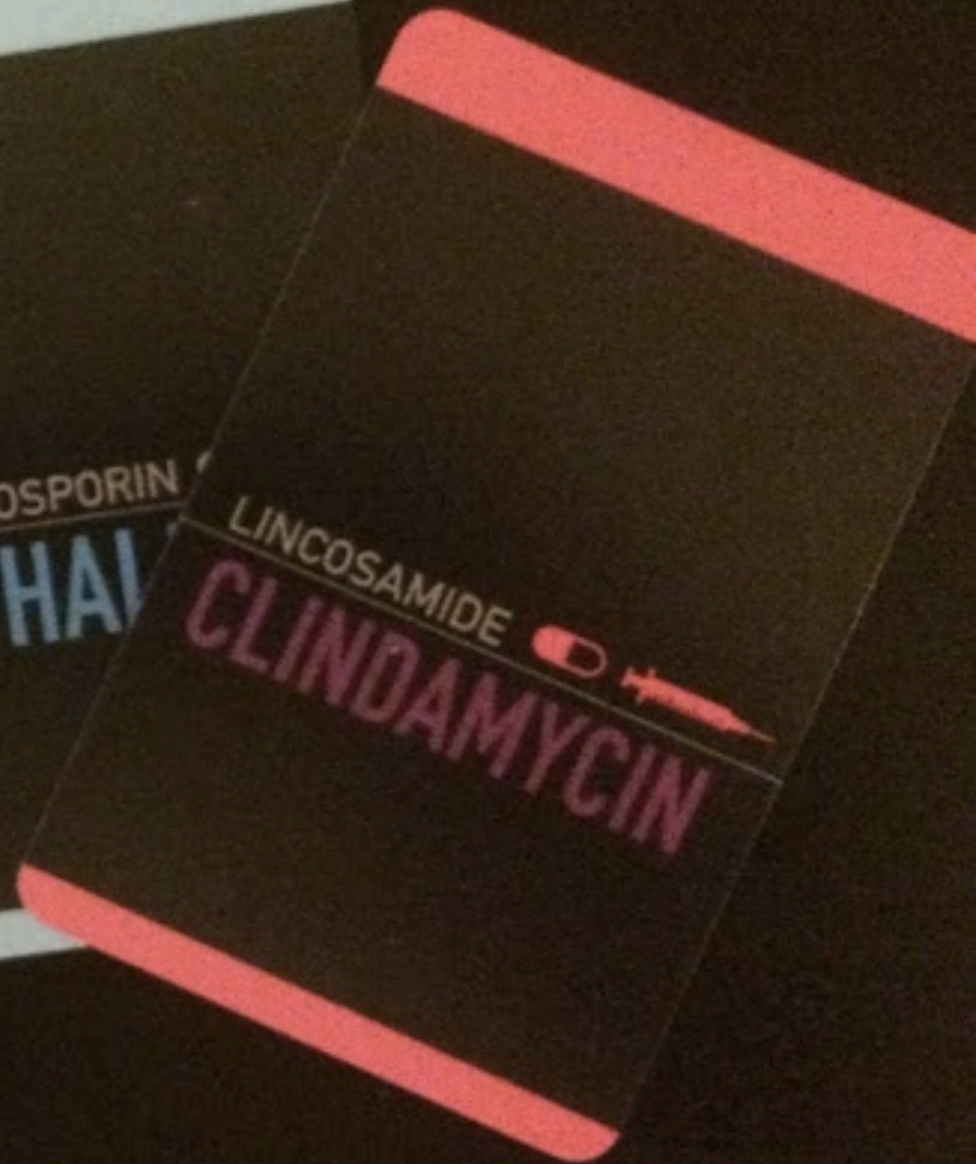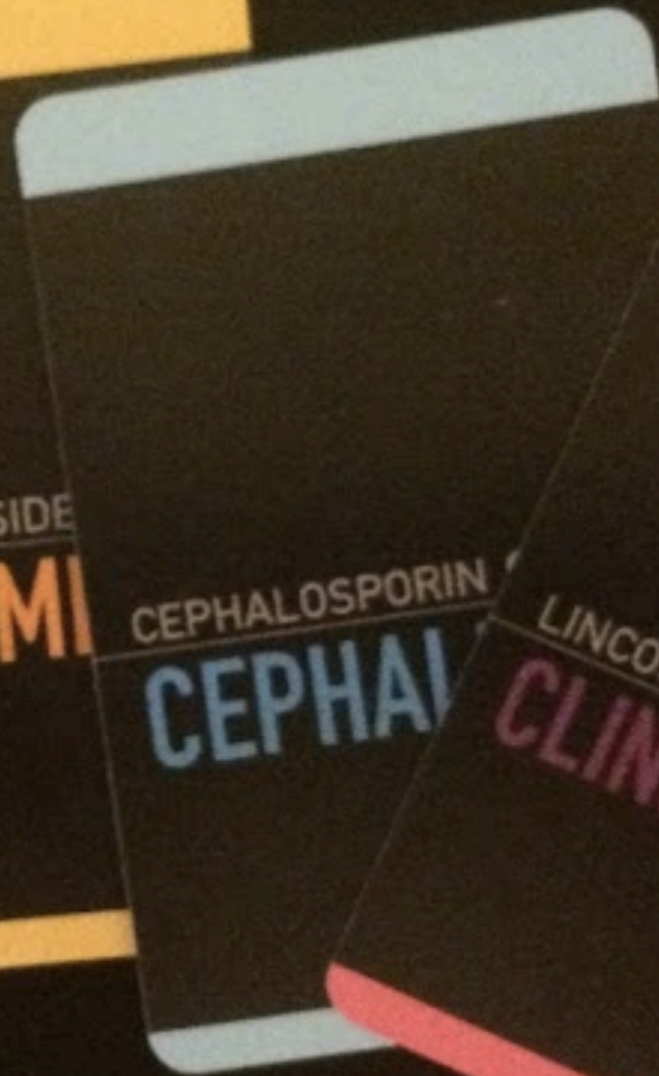
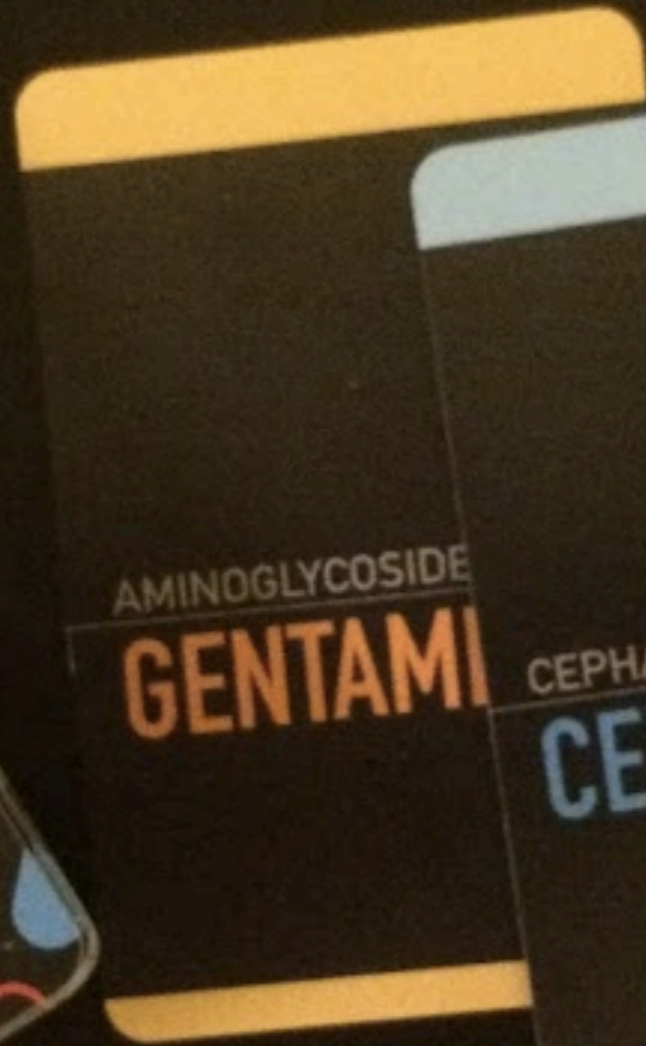
Booklets: [\[see details\]](#)

None

[start your design](#)

[\[No time or would like our help?\]](#)

[Choose another card size](#)



\$20 AND THE SAME SOFTWARE AS THIS 
PRESENTATION

MINIMUM VIABLE 

PELVIC INFLAMMATORY DISEASE

- Eighteen-year-old sexually active women presenting with vaginal discharge, vomiting, lower abdominal pain and fever found to have cervical motion tenderness

6

C. DIFF

- Twelve-year-old with history of frequent admissions for aspiration pneumonia presenting with recurrence of *Clostridium difficile* infection.

4

FEVER

- Fifteen-year-old in induction chemotherapy for SR-ALL presents with fever to 38.5 and found to have absolute neutrophil count of 200/mm³. Well appearing and no source on exam.

3


AZITHROMYCIN



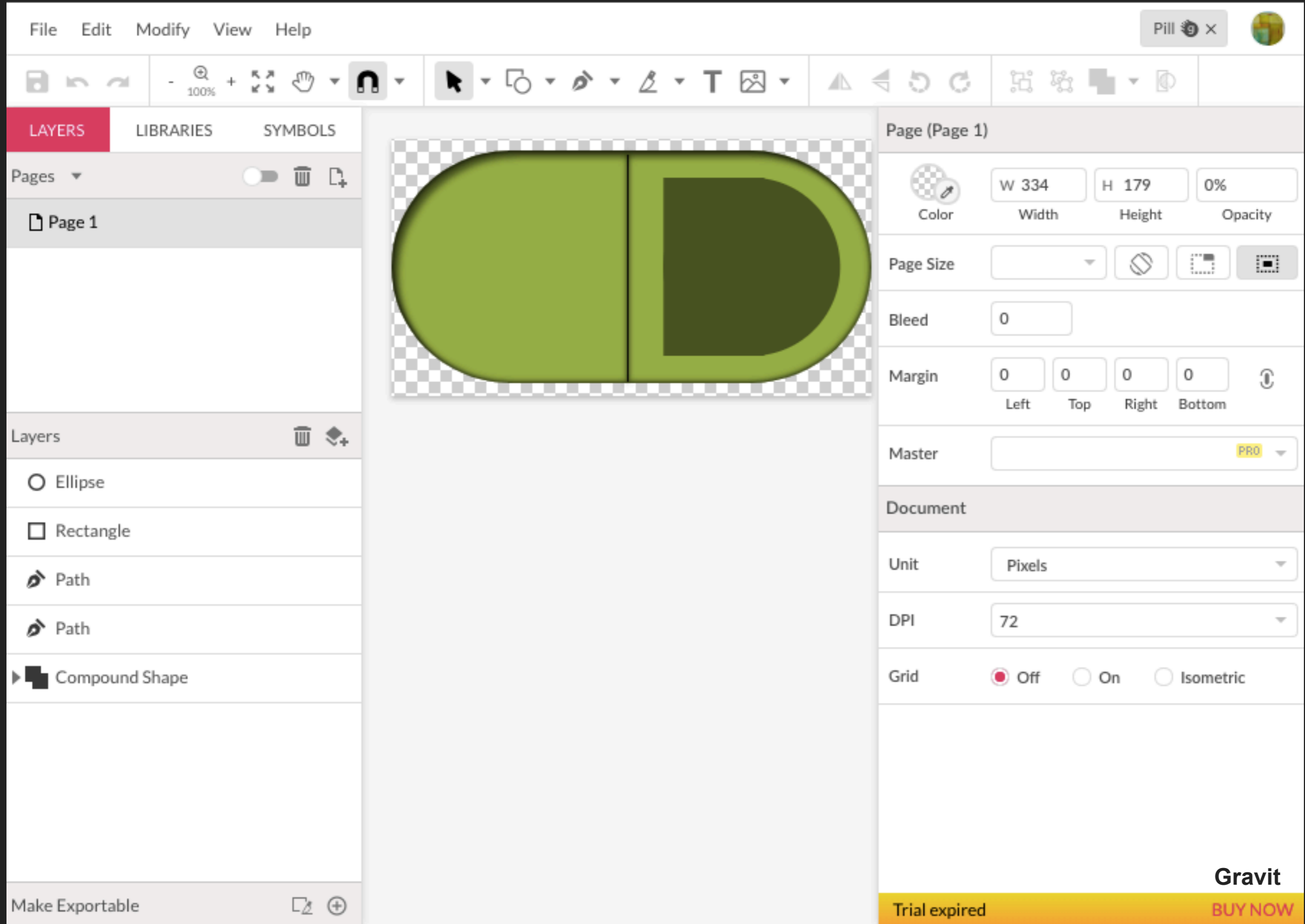
S. pneumoniae



Stacked antibiotic cards:

- OBSE
- PENICIL AM
- PENICIL AM
- MACROLIDE AZITHRO
- LINCOSAMIDE  CLINDAMYCIN

ONLINE IMAGE EDITORS



The screenshot displays the Gravit online image editor interface. At the top, there is a menu bar with 'File', 'Edit', 'Modify', 'View', and 'Help'. Below the menu is a toolbar with various editing tools like selection, zoom, pan, and drawing tools. The main workspace shows a green pill-shaped graphic on a checkered background. On the left, there are panels for 'LAYERS', 'LIBRARIES', and 'SYMBOLS'. The 'LAYERS' panel shows a list of layers: 'Ellipse', 'Rectangle', 'Path', 'Path', and 'Compound Shape'. On the right, there is a properties panel for 'Page (Page 1)' with fields for 'Color', 'Width' (334), 'Height' (179), and 'Opacity' (0%). Below this are sections for 'Page Size', 'Bleed', 'Margin', 'Master', 'Document', 'Unit' (Pixels), 'DPI' (72), and 'Grid' (Off). A yellow banner at the bottom right says 'Gravit Trial expired BUY NOW'.

CARDS IN HAND? IMPORTANT INFO IN ONE CORNER OR EDGE

Card at Work

DESIGNING CARDS
FOR T


CA
CO



ROCKY MOUNTAIN SPOTTED FEVER

1

› Seven-year-old with fever headache and acral rash with palm and sole involvement after travel to Missouri. CBC shows thrombocytopenia. Treatment is started while awaiting serology.




4

BARTONELLA ADENITIS

1

› Six-year-old with unilateral cervical lymphadenopathy and kitten exposure. Bartonella IgG titer is greater than 1:256.



2

ANTHRAX EXPOSURE

1

› Twelve-year old boy with concern for exposure to aerosolized anthrax in terror attack.




4

COMMUNITY ACQUIRED PNEUMONIA

1

› Vaccinated Four-year-old with a three day history of fever, cough and congestion. Mild increased work of breathing and crackles in right posterior lung field.




2

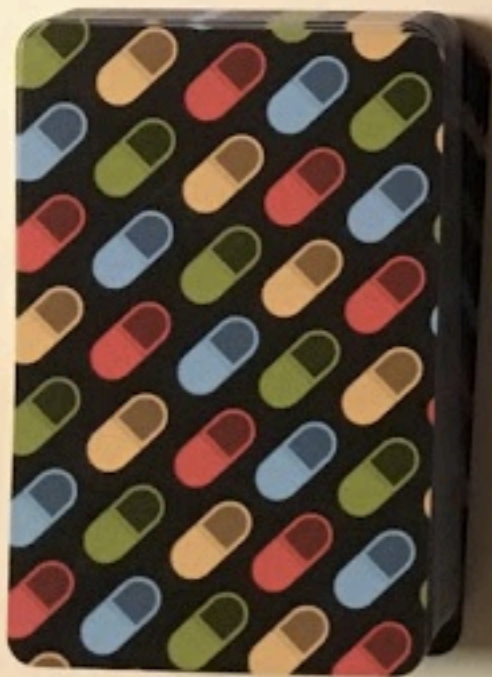
APPENDICITIS

1

› Eight-year-old boy with acute onset of periumbilical pain now migrating to the right lower quadrant. Abdominal ultrasound is consistent with appendicitis.



4




OBSERVATION
"LET'S KEEP AN EYE ON THIS FOR A COUPLE DAYS"

DOXYCYCLINE
TETRACYCLINE

AMOXICILLIN
PENICILLIN

AZITHROMYCIN
MACROLIDE

CIPROFLOXACIN
FLUOROQUINOLONE



CEFTRIAXONE + AZITHROMYCIN



Neisseria gonorrhoeae

P29

Sentence ▾ 40px ▾    

Categories ▾ Language ▾ Font Properties ▾

Viewing 977 of 977 font families

Sort by: Trending now ▾

Roboto 
Christian Robertson (12 styles)

All their equipment and instruments are alive.

Gelasio 
Eben Sorkin (8 styles)

A red flare silhouetted the jagged edge of a wing.

Bangers 
Vernon Adams (1 style)

I WATCHED THE STORM, SO BEAUTIFUL YET TERRIFIC.

Open Sans 
Steve Matteson (10 styles)

Almost before we knew it, we had left the ground.

REDDIT!

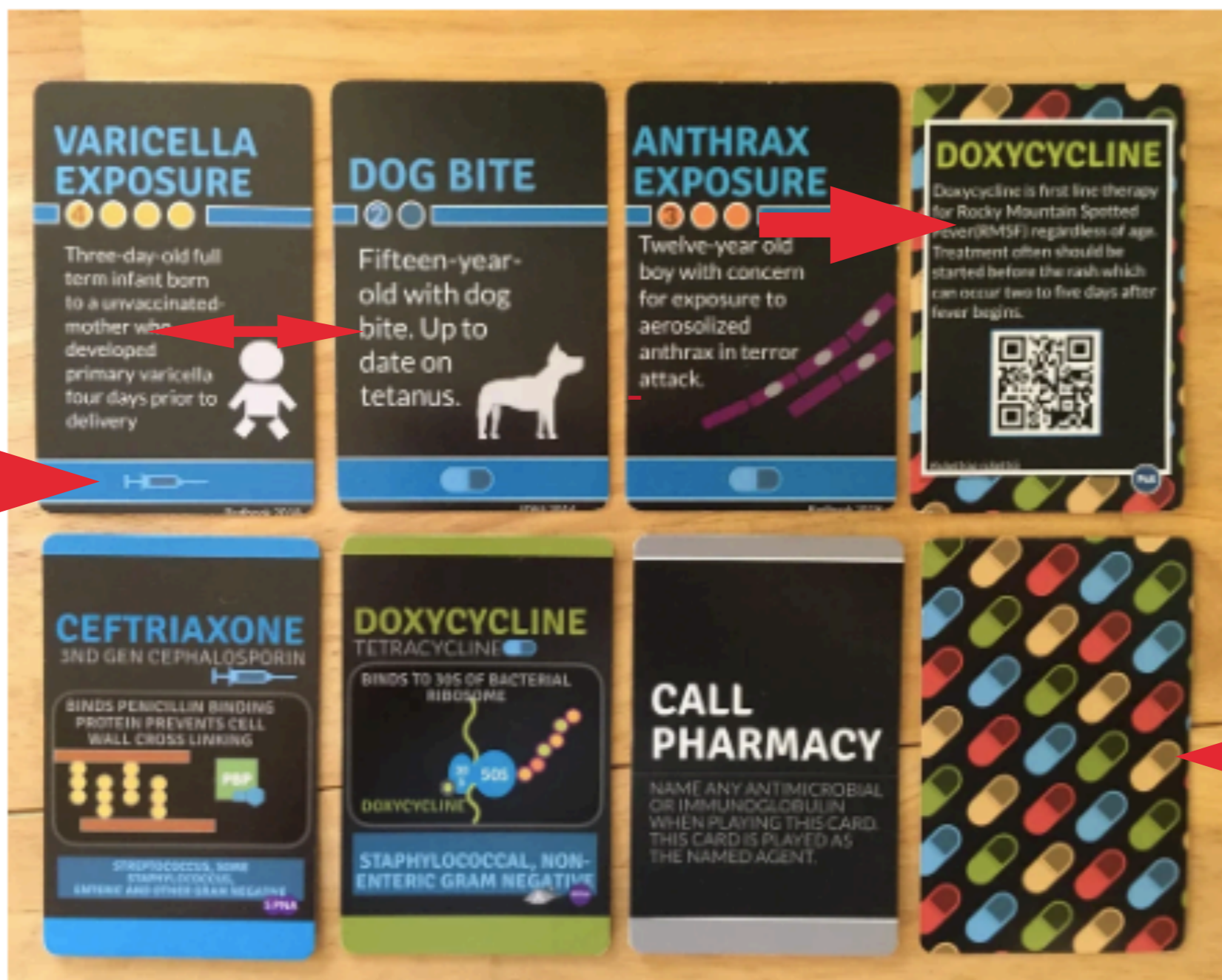

57



r/tabletopgamedesign · Posted by u/mctc 10 months ago

Feedback on card design?



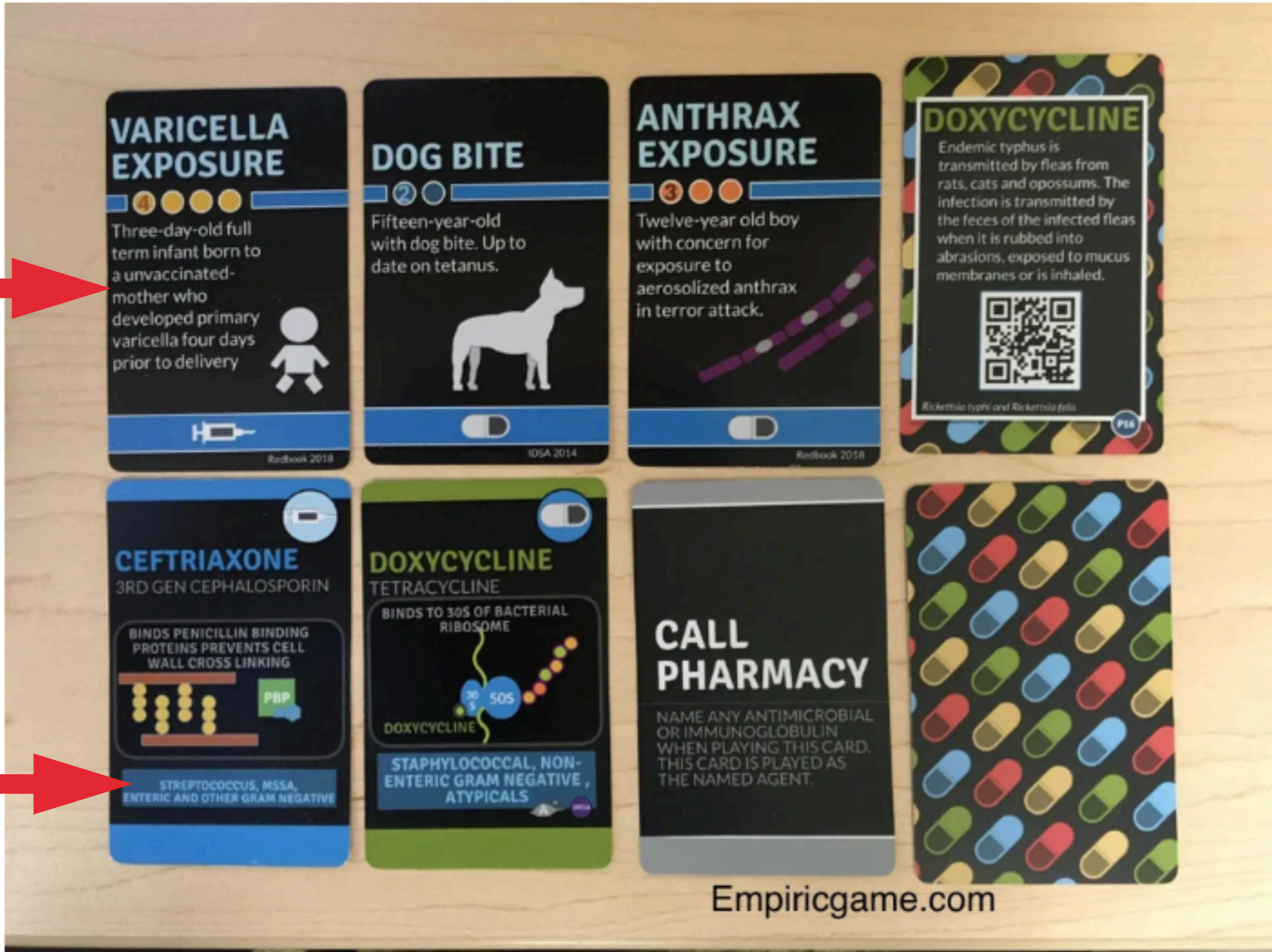55 Comments Share ...

95% Upvoted



Posted by u/mctc 8 months ago

Thanks for the card design feedback here is the new printing



Empiricgame.com

13-year-old with sickle cell disease admitted for vaso-occlusive crisis suddenly develops fever, shortness of breath, and is found to have a new focal infiltrate on chest x-ray.

Healthy three-year-old with fever and diarrhea is well appearing. She has a 3" turtle at home. Stool culture is positive for non-typhoidal Salmonella.

Four-year-old with severe abdominal pain initially concerning for appendicitis. Progressive fever and diarrhea lead to admission for dehydration. Stool testing positive for *C. jejuni*.

Six-year-old with acute onset of tender, red, enlarged left anterior cervical lymph node.



JAMA 2014

Redbook 2018



Redbook 2018



Nelsons 2018

LYME



Twelve-year old with growing circular red rash appearing one week after tick removal at same site while camping in Pennsylvania.

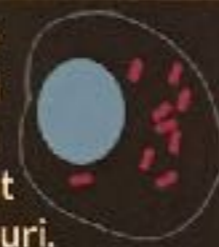

CDC 2017

ROCKY MOUNTAIN SPOTTED FEVER



Seven-year-old with fever, headache, and acral rash with palm and sole involvement after travel to Missouri. CBC shows thrombocytopenia. Treatment is started while awaiting serology.

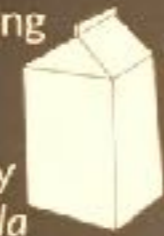

CDC 2017

BRUCELOSIS



Nine-year-old with history of unpasteurized milk consumption presenting with arthritis and intermittent fevers, found to have serology consistent with *Brucella* infection.




AAP 2014

N MENINGITIDIS EXPOSURE



Vaccinated nineteen-year-old whose roommate was diagnosed with *N. meningitidis* meningitis.



OR



Redbook 2018

ANTHRAX EXPOSURE



Twelve-year-old boy with concern for exposure to aerosolized anthrax



DOG BITE



Fifteen-year-old with dog bite. Up to date on tetanus.



SECONDARY SYPHILIS



Febrile sexually active twenty-year-old, initially diagnosed with

PLAGUE



Thirteen-year-old with acute onset of 40° fever and left inguinal lymph node

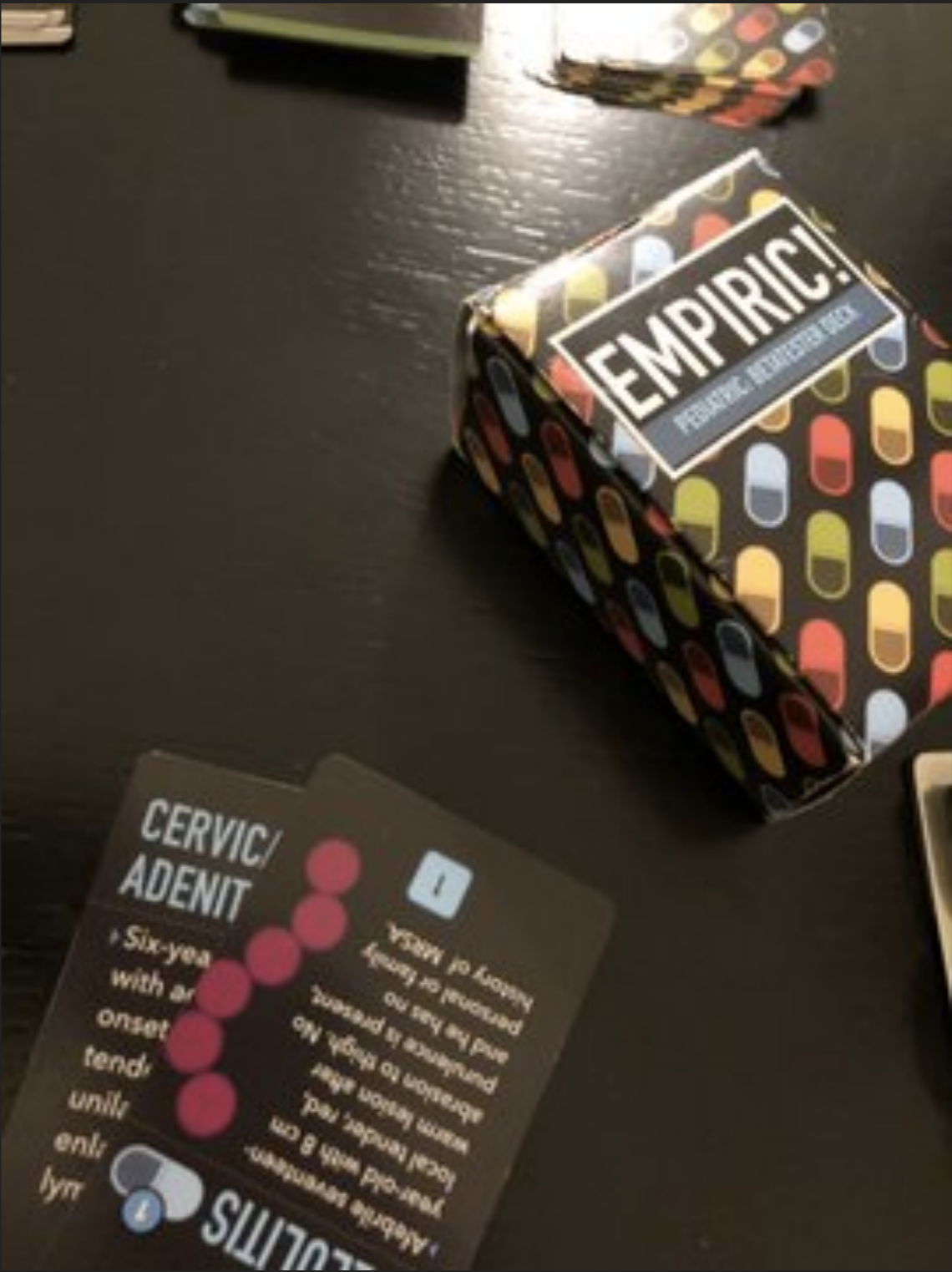


ITERATION ON PRINTED COPIES



**FEEDBACK/
PLAY-TESTING**

MAILING OUT COPIES FOR FEEDBACK 📩



GOT FEEDBACK ON TWO OF MANY SENT OUT

13mo

Questions

Responses

1



Empiric

All questions optional

Comments about gameplay

Long answer text

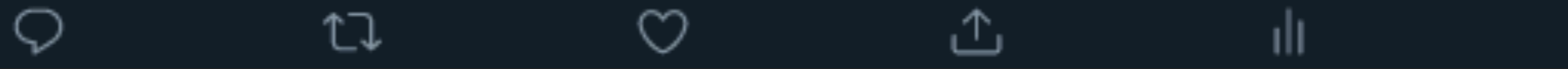
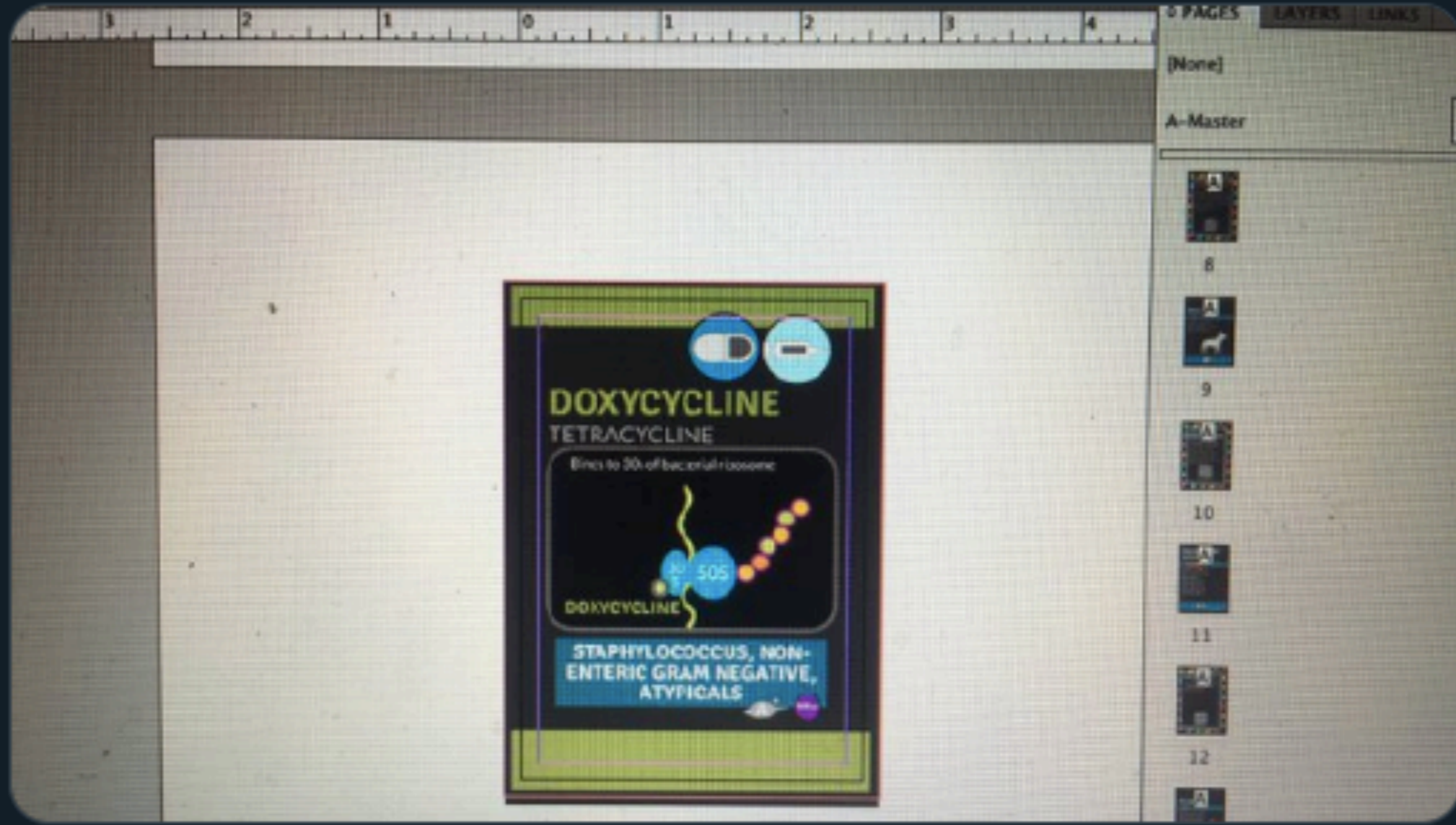
Comments about educational value

Long answer text



Empiric - Antibiotic Card Game @EmpiricGame · Jul 4, 2019

Uploaded and ordered a proof of the updated beta copy after my senior resident found more punctuation problems than I was comfortable with. Beta release in 2 weeks. [#andthistimelmeanit](#)



Questions

Responses

2



Empiric

All questions optional

Comments about gameplay

Long answer text

Comments about educational value

Long answer text

SOCIAL MEDIA

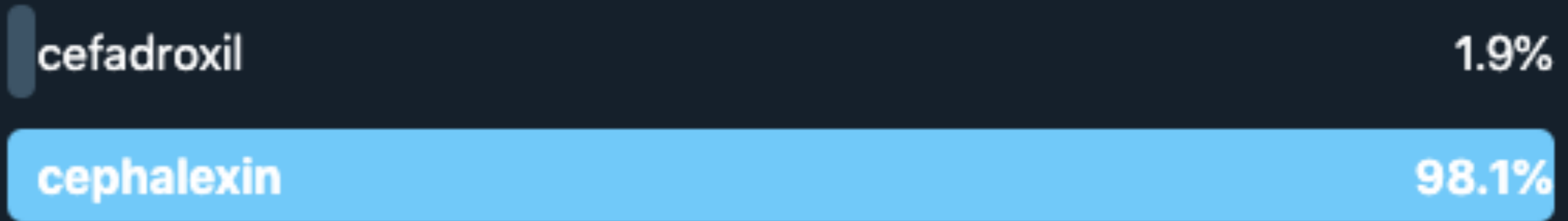

Michael Cosimini @MichaelCosimini · Nov 24, 2019

Decision making regarding meds to include in @EmpiricGame

Please answer if you practice in North America.

I am more familiar with:



107 votes · Final results

 5

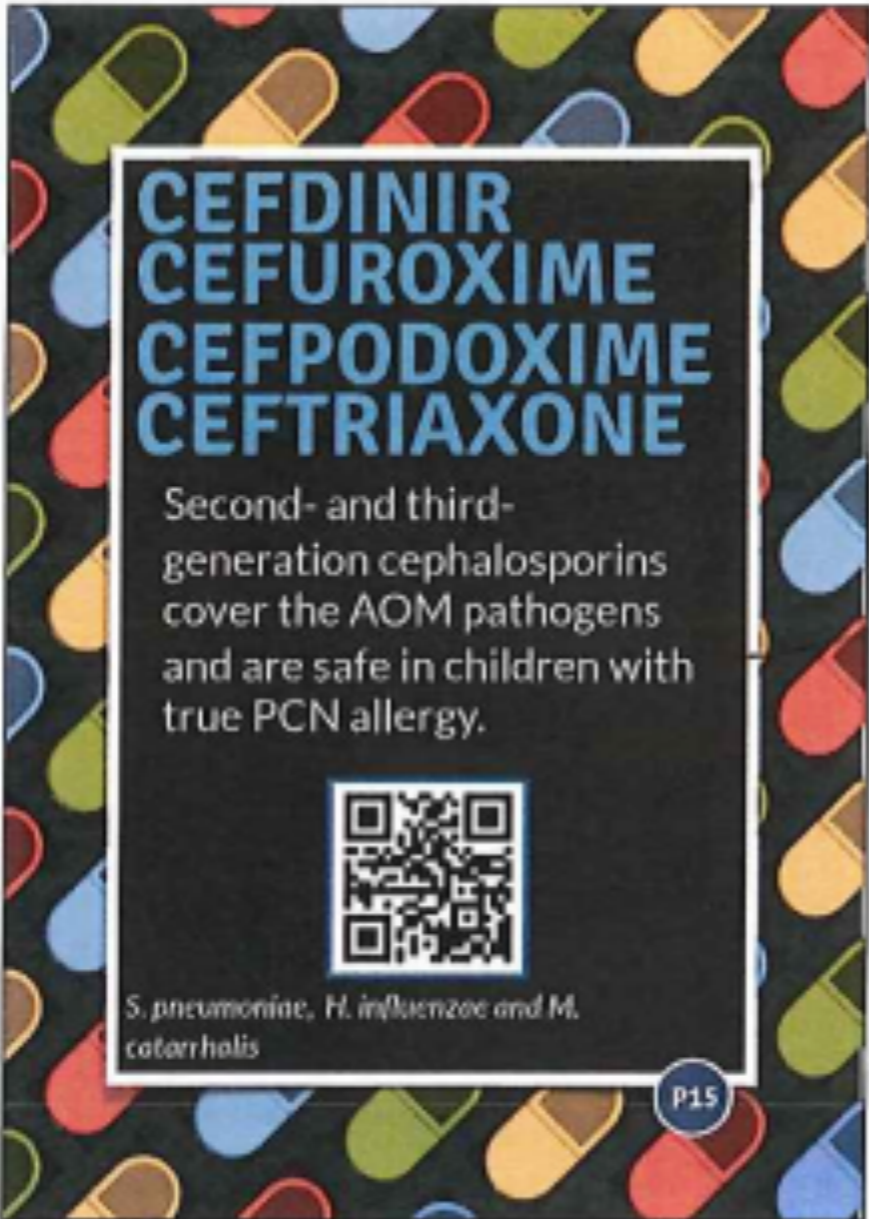
 1

 2




[Show this thread](#)

GETTING FEEDBACK ON PDF



**CEFDINIR
CEFUROXIME
CEFPODOXIME
CEFTRIAXONE**

Second- and third-generation cephalosporins cover the AOM pathogens and are safe in children with true PCN allergy.



S. pneumoniae, H. influenzae and M. catarrhalis

P15

-if allergy is mild (hives)

GAME DESIGN/ EDUCATION

DESIGN FOR THE HUMAN ANIMAL 

PEOPLE WILL DO WHAT THEY WILL DO 



[SERIES](#)

[ARCHIVE](#)

[ABOUT](#)

[CONTACT](#)



#173: GAME DESIGN AXIOMS



THE GAME DESIGN ROUND TABLE
#173: Game Design Axioms

30%

00:00:00 / 00:39:19

↻ 30



libsyn

COMPETITION IS OK

Published: 29 August 2016

A serious game skills competition increases voluntary usage and proficiency of a virtual reality laparoscopic simulator during first-year surgical residents' simulation curriculum

[Mostafa El-Beheiry](#) , [Greig McCreery](#) & [Christopher M. Schlachta](#)

[Surgical Endoscopy](#) **31**, 1643–1650(2017) | [Cite this article](#)

697 Accesses | **5** Citations | **3** Altmetric | [Metrics](#)

MAKE IT SIMPLE



DOXYCYCLINE
TETRACYCLINE
BINDS TO 30S OF BACTERIAL RIBOSOMES
STAPHYLOCOCCAL NON-ENTERIC GRAM NEGATIVE



LEMIERRE SYNDROME
Sixteen-year-old boy with one week progressive sore throat, unilateral neck pain and facial swelling. Ultrasound shows internal jugular venous thrombosis.



SEPTIC ARTHRITIS
Vaccinated sixteen-year-old with fever and acute swelling and warmth of the right knee. Aspiration consistent with bacterial arthritis. MRSA locally prevalent and he is not sexually active.

OTITIS MEDIA
One-year-old with fever two days of otalgia and otoscopy consistent with unilateral acute otitis media. No recent antibiotics.

N MENINGITIDIS EXPOSURE
Vaccinated nineteen-year-old whose roommate was diagnosed with N meningitidis meningitis.

BARTONELLA ADENITIS
Six-year-old with unilateral cervical lymphadenopathy and kitten exposure. Bartonella IgG titer is greater than 1:256.


RIFAMPIN
INHIBITS RNA POLYMERASE
RELAPSE
RIFAMPIN
RIFAMPIN
RIFAMPIN
RIFAMPIN



ABSCCESS
Feverile 30-year-old with history of MRSA skin infections admitted after nursing large abscess drained in ED.

ANTHRAX EXPOSURE
Twelve-year-old boy with concern for exposure to aerosolized anthrax in terror attack.

ENDEMIC TYPHUS
Seven-year-old with history of oral exposure presents with acute onset of fever, headache and myalgia. On day four of illness a diffuse rash appears. Thrombocytopenia, hyponatremia and transaminitis are noted.



MAKE IT SMALLER



GAME DOES NOT STAND ALONE

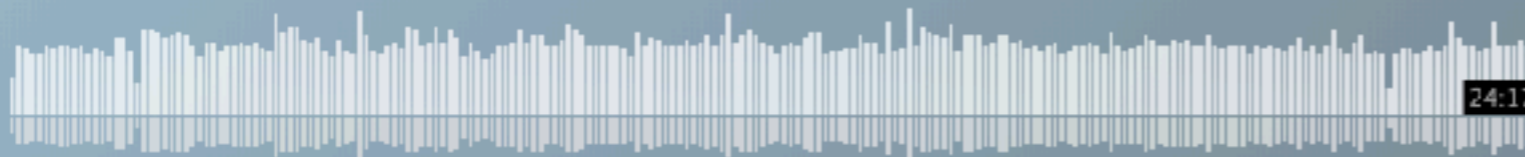

Empiric Pediatric

Antibiotics in Pediatrics: Upper And Lower Respiratory Infections

3 months ago

Learning



Write a comment



▶ 147 ♥ 1 More stats



Parul and Michael discuss commonly used antibiotics in pediatrics.

- Episode 1 includes:
- Group A Streptococcal Pharyngitis
 - Acute Otitis Media
 - Sinusitis
 - Community Acquired Pneumonia.



Replace tracks with Pro

Make changes to your tracks without losing your stats

[Try Pro Unlimited](#)



AZITHROMYCIN OBSERVATION

Bartonella henselae is a common cause of adenopathy in children. Treatment is not uniformly required, but when treated, azithromycin is the drug of choice.



Bartonella henselae

P1

BARTONELLA ADENITIS

Give feedback on this card

***Bartonella henselae* is a common cause of adenopathy in children. Treatment is not uniformly required but when treated azithromycin is the drug of choice.**

Bartonella henselae

Common cause of regional adenopathy in children typically with exposures to kittens. IgG Titer >1:256 is consistent with current infection while lower titers may reflect previous exposure.

Azithromycin has been shown to speed improvement of lymphadenopathy but is not always necessary in mild cases in immunocompetent hosts. Severe cases and cases in immunocompromised hosts should be treated.

Other manifestations include Oculoglandular syndrome (conjunctivitis and ipsilateral preauricular lymphadenopathy) as well as painless vision loss from neuroretinitis.

Potential alternative agents include: azithromycin, clarithromycin, ciprofloxacin, doxycycline, trimethoprim-sulfamethoxazole, rifampin, and gentamicin

References:

American Academy of Pediatrics. *Bartonella henselae* (Cat-Scratch Disease). In: Kimberlin DW, Brady MT, Jackson MA, Long SS, eds. Red Book: 2018 Report of the Committee on Infectious Diseases. American Academy of Pediatrics; 2018;



PROMOTION

 **Empiric - Antibiotic Card Game**
627 Tweets



Empiric
15min Pediatric
MS1+
2-4 Players

[Edit profile](#)

Empiric - Antibiotic Card Game
@EmpiricGame

Card game for guideline based antimicrobial use. Pediatric first Ed
drivethrucards.com/product/270763... #MedEd

📍 Los Angeles CA EmpiricGame.com 📅 Joined April 2019

755 Following **455** Followers

Tweets Tweets & replies Media Likes

VIDEO



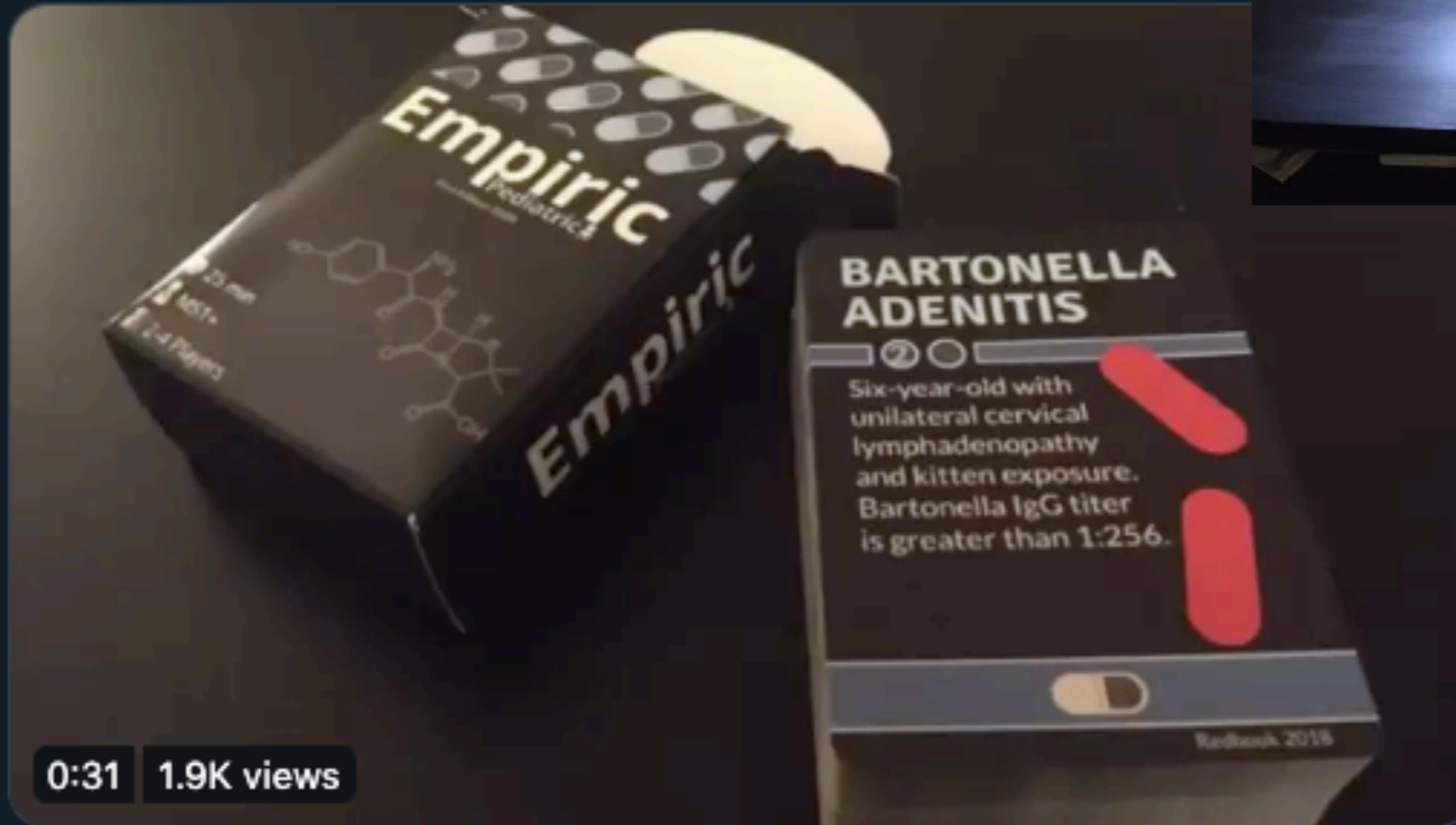Empiric - Antibiotic Card Game @EmpiricGame · Jan 10
Empiric Pediatric is a 2-4 player #MedEd card game to teach guideline based antibiotic selection.

Official release is January 15

EmpiricGame.com

FB: facebook.com/groups/6097592...

Twitter and Instagram: @EmpiricGame



3

17

38



PRINT ON DEMAND 

Browse Categories

- Type ▾
- Theme ▾
- Age ▾
- Players ▾
- Publishers ▴
 - Empiric
- Price
 - Pay What You Want
 - Free
 - \$ to \$ >>
- Card Creators ▾

Publisher

Empiric
[Publisher Website](#) 
[Contact](#)

Search... 

[Advanced Search](#)



You are viewing this item as a customer > [View as the creator](#)

Empiric Pediatric

From Empiric

Premium US Poker Card(s) in Tuckbox


\$13.99

You Have Purchased This Product

[ADD TO CART](#) 

[ADD TO WISHLIST >](#)

Empiric is an infectious disease card game for 2-4 players.

 empiric pediatric box

The game is designed for education for physicians and medical trainees including medical students, residents (pediatrics, EM), PA students, NP students, and pharmacy students.

Content is primarily derived from IDSA and AAP guidelines to teach antimicrobial selection for common and important infections. **The content is specific to North American guidelines.**

This package is the 2020 First Edition which contains 86 play cards including 40 infection cards with treatment options, learning points and links to further online content.

Empiric

Monthly Totals by Product

2020-01-01 through 2020-01-31

Month	Model	Product	Total Sold	Gross Sales	Earnings
1-2020		Empiric Pediatric	44	\$620.56	\$100.20
SUBTOTAL - 1-2020:			44	\$620.56	\$100.20
Grand Totals:			44	\$620.56	\$100.20

- ▶ 9c per card
- ▶ 2.50 for custom box
- ▶ Total 10.60
- ▶ Markup to 13.99
- ▶ 3.39 (65% to me)
- ▶ Low risk option for publishing to niche

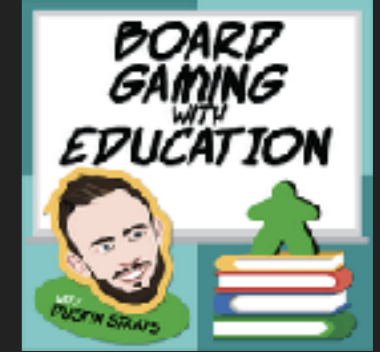**PERFECT IS THE
ENEMY OF DONE**

NEXT STEPS

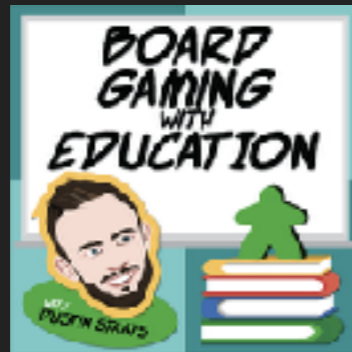- ▶ Scholarship
- ▶ Expansions

RESOURCES

Podcasts

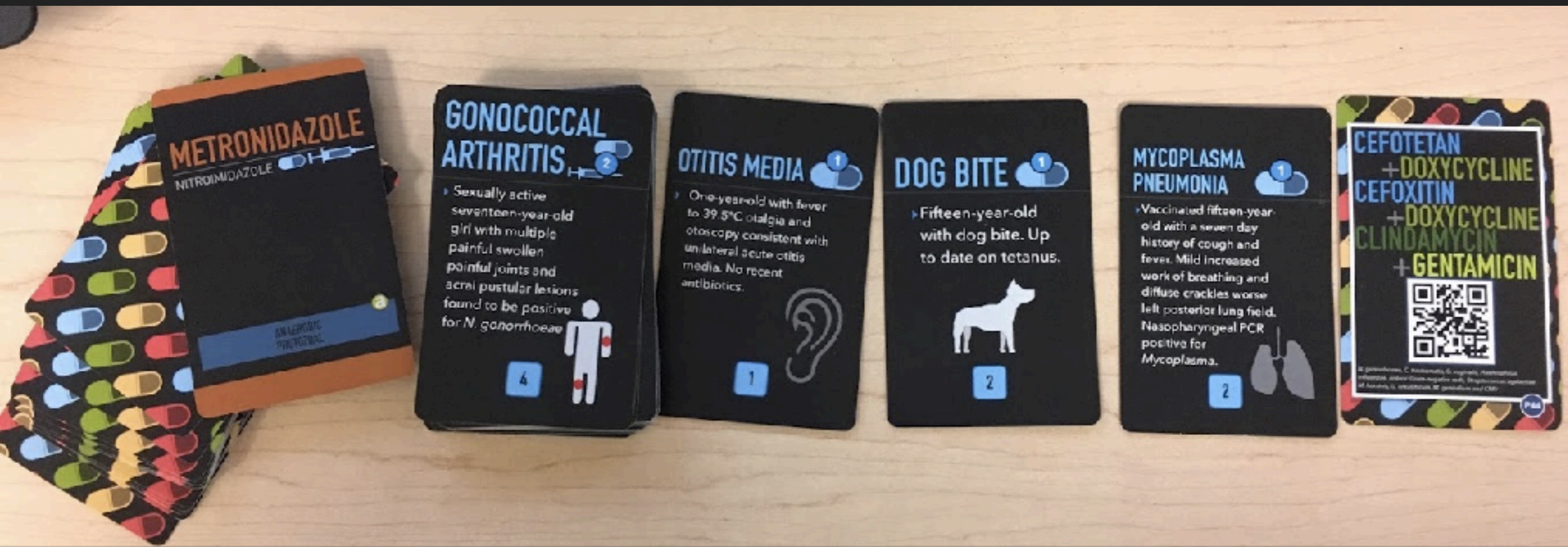

Facebook



Reddit





METRONIDAZOLE
 NITROIMIDAZOLE

AN AEROBIC
 PROTOZOAL

GONOCOCCAL ARTHRITIS

Sexually active seventeen-year-old girl with multiple painful swollen joints and acral pustular lesions found to be positive for *N. gonorrhoeae*

4

OTITIS MEDIA

One-year-old with fever to 39.5°C otalgia and otoscopy consistent with unilateral acute otitis media. No recent antibiotics.

1

DOG BITE

Fifteen-year-old with dog bite. Up to date on tetanus.

2

MYCOPLASMA PNEUMONIA

Vaccinated fifteen-year-old with a seven day history of cough and fever. Mild increased work of breathing and diffuse crackles worse left posterior lung field. Nasopharyngeal PCR positive for *Mycoplasma*.

2

CEFOTETAN + DOXYCYCLINE
CEFOXITIN + DOXYCYCLINE
CLINDAMYCIN + GENTAMICIN

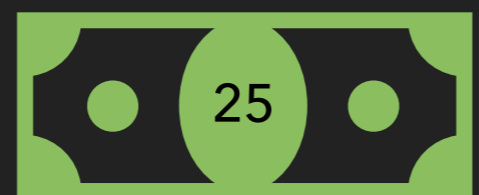QR code

St gonorrhoeae, C. trachomatis, G. vaginalis, Haemophilus influenzae, enterococci, negative with, Streptococcus agalactiae, St. aureus, S. pneumoniae, St. pneumoniae and CMV


1/20



MPC[®]
 MAKEPLAYINGCARDS.COM



Emporic



PEDIATRIC



2-5 PLAYERS



MS1+

**@MICHAELCOSIMINI
2019**